

A mixed reality simulator augmented with real-time 3D visualization helps develop a modified thoracic paravertebral block

Ihnatsenka B, Le-Wendling L, Coleman CJ, Lizdas DE, Lampotang S

Department of Anesthesiology, Center for Safety, Simulation & Advanced Learning Technologies,

Clinical and Translational Science Institute Simulation Core, University of Florida College of Medicine, Gainesville, FL

This work supported in part through grants from the Department of Defense W81XWH-14-1-0113, the NIH/NCATS Clinical and Translational Science Award to the University of Florida UL1 TR000064 and the American Society of Regional Anesthesia.



Introduction

The main techniques for ultrasound (US)-guided thoracic paravertebral block (TPVB) are sagittal paramedian (SP) and transverse (T, lateral to medial). A goal of TPVB is to safely guide a needle tip into a thoracic paravertebral space without striking the lungs. In TPVB-SP¹, a sharp needle insertion angle to avoid the transverse processes and an unfavorable insonation beam incidence angle to the lungs make the needle and lungs hard to acquire in an US image. For TPVB-T², the needle and lungs are easier to acquire in an US image but the needle trajectory is towards the neuroforamen and risks spinal cord injury because needle advancement/catheter placement are towards the neuraxis. A technique where the needle and lung are readily acquired in an US image but without aiming a needle at the spine is therefore desirable. In addition, conventional US imaging of 3D anatomy generates 2D cross-sections, creating cross-sectional literacy issues for spatially-challenged users and novices and making it hard, even for experts, to fully appreciate the 3D anatomy as it relates to TPVB.



Fig 1. The mixed reality simulator

Methods

To help trainees develop 3D, anatomical mental models and map 2D sonoanatomy onto 3D anatomy, visual augmentation was added to a mixed reality simulator of thoracic regional anesthesia via a 3D, real-time, color visualization of a virtual anatomic thoracic spine, probe/insonation plane and needle corresponding to the position and orientation of a tracked physical spine and US probe and needle counterparts, respectively (see Figure 1).

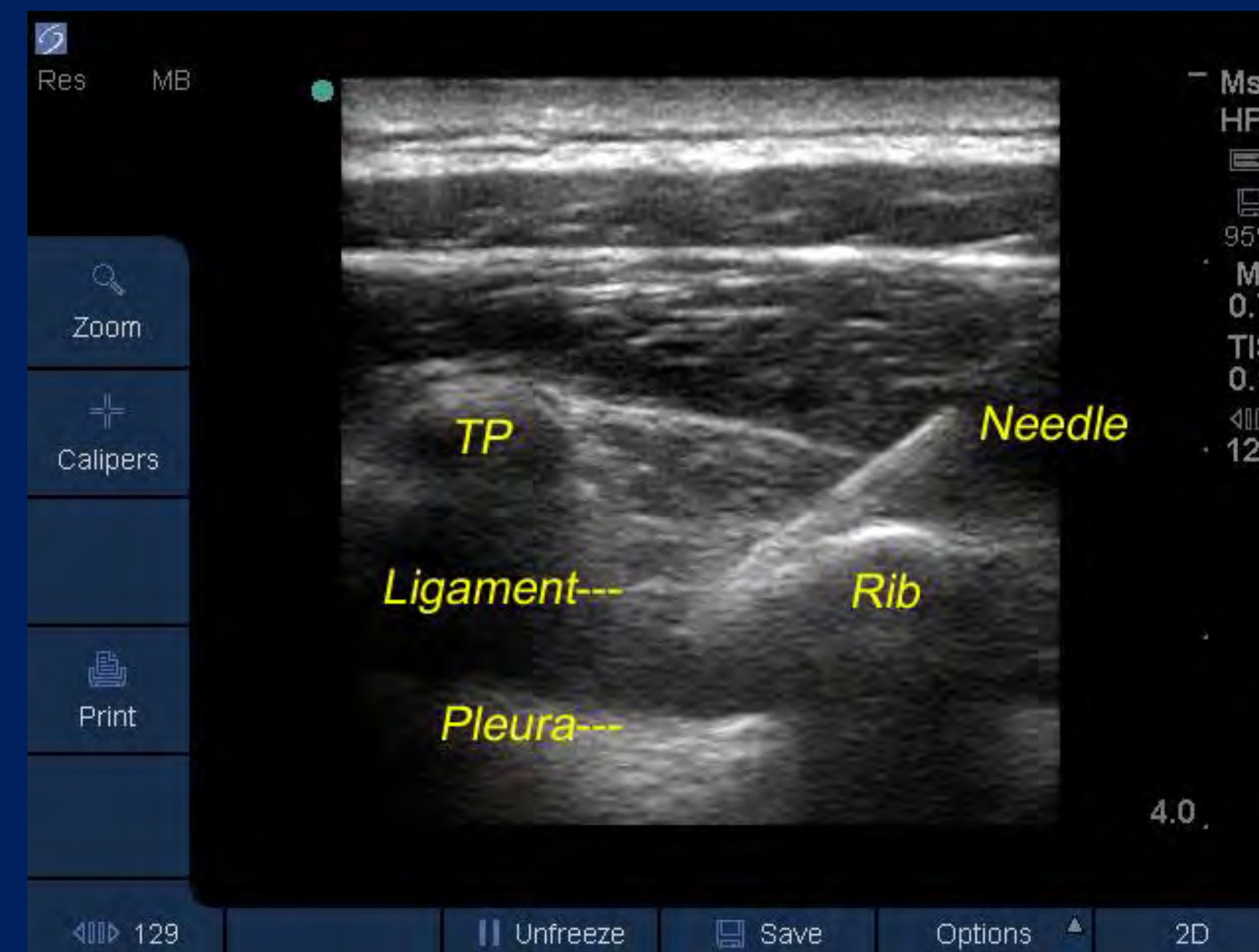


Fig 2a. The SP-Oblique in an actual patient

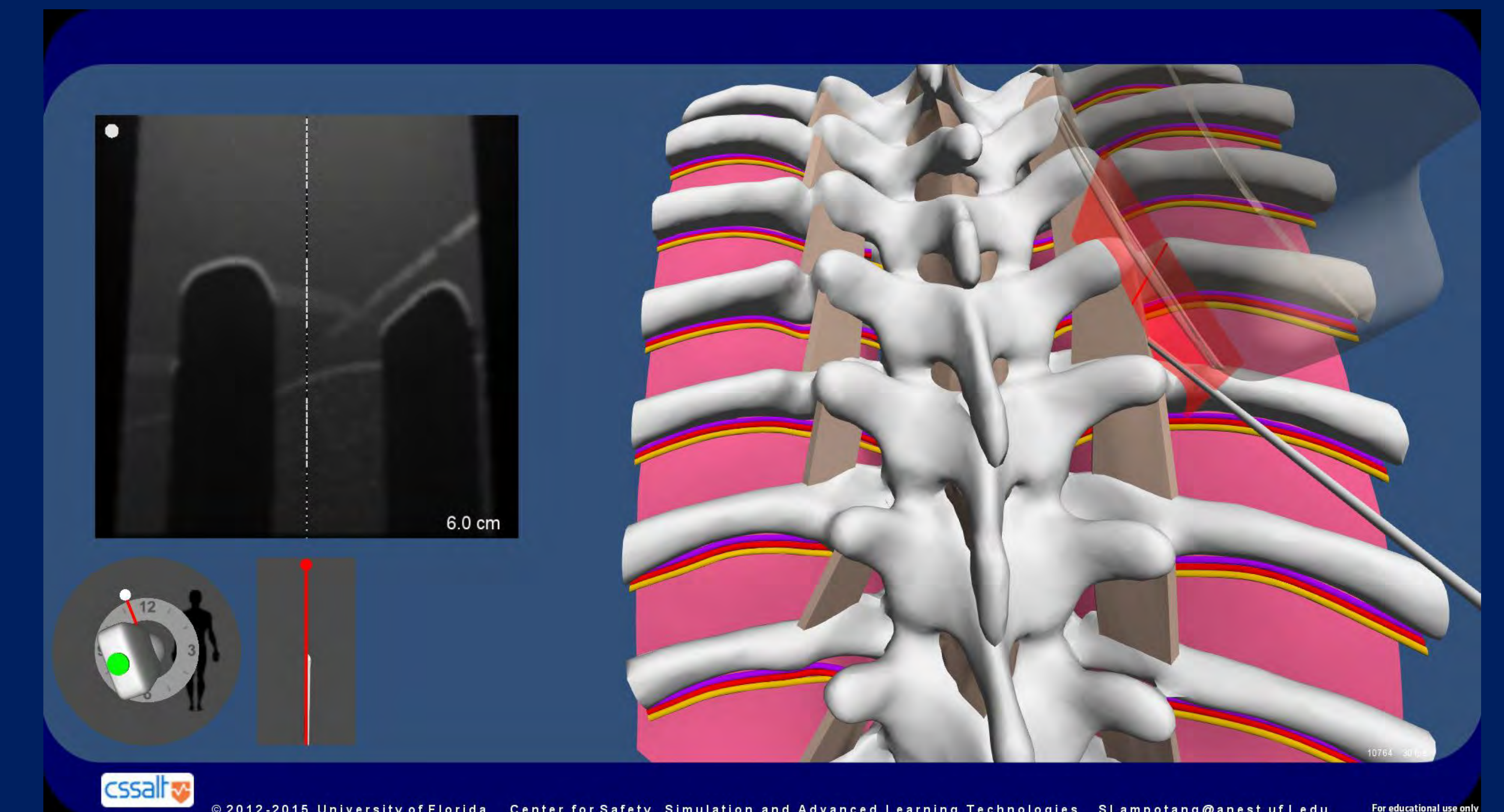


Fig 2b. The SP-Oblique in the mixed reality simulator

Results

While working with the simulator with its 3D visualization activated, an expert in TPVB (BI) developed a modified sagittal paramedian oblique (SP-oblique) TPVB technique that enhances needle visibility in the US image without directing the needle at the spine. When the recommended TPVB-SP insonation plane (12 o'clock) is modified to SP-oblique (11 or 1 o'clock; Fig. 2b), the needle enters over a rib (lower, more ventral bony obstacle than the transverse process), allowing a shallower trajectory that makes the needle easier to acquire in the US image and more optimal imaging of the lung (Fig. 2a). After extensive simulator-based evaluation, the modified TPVB-SP-oblique technique was successfully reproduced on patients and locally adopted into clinical practice.

Conclusions

Our hypothesis that 3D visualization helped develop the modified technique is supported by the observation that although our clinical co-authors used the US-guided SP TPVB technique for years, the subtly different SP-oblique approach (including its advantages) was previously unknown and did not occur to them, until 3D visualization became available through the mixed reality simulator.

References

1. Riain SCO, Donnell BO, Cuffe T, Harmon DC, Fraher JP, Shorten G: Thoracic paravertebral clock using real-time ultrasound guidance. *Anesthesia & Analgesia*, 2010;110:248-51
2. Cowie B, McGlade D, Ivanusic J, Barrington MJ. Ultrasound-guided Thoracic Paravertebral Blockade: A Cadaveric Study. *Anesthesia & Analgesia*. 2010; 110: 1735-1739

The U.S. Army Medical Research Acquisition Activity, 820 Chandler Street, Fort Detrick MD 21702-5014 is the awarding and administering acquisition office. This work was supported by the Department of the Office of the Assistant Secretary of Defense for Health Affairs under Award No. W81XWH-14-1-0113. Opinions, interpretations, conclusions and recommendations are those of the authors and are not necessarily endorsed by the Department of Defense.

Samsun (Sem) Lampotang, PhD slampotang@anest.ufl.edu

